



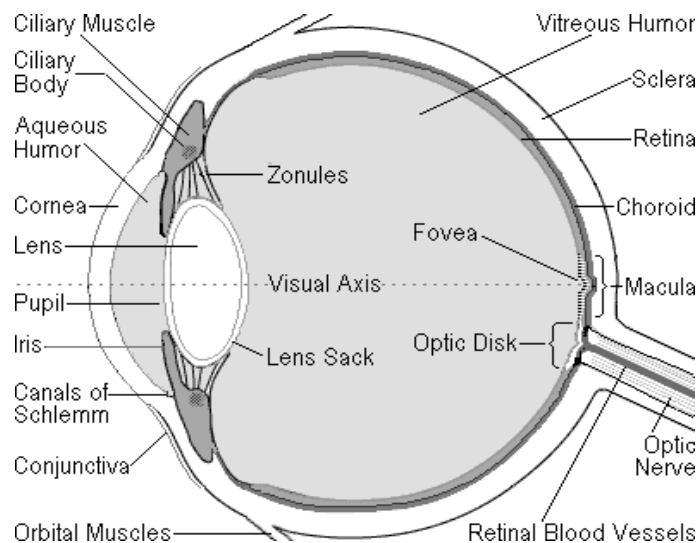
Uveitis Information Group Factsheet

About Birdshot Chorioretinopathy

Please use this fact sheet as background information to help discussion with your doctors. Individual cases may vary enormously and so the best information will always come from your doctors. The information in this sheet has been checked for accuracy by leading Uveitis Specialists.

Birdshot Chorioretinopathy (BSRC) is a rare and potentially blinding chronic posterior uveitis. Uveitis means inflammation of the uvea, the part of the eye that is made up of the iris, the choroid of the eye, and the ciliary body. The uvea provides most of the blood supply to the retina.

In the picture of the eye below, you can see the position of the iris, the choroid and the ciliary body.



What are the Symptoms of BSRC?

Usually, the initial symptoms of BSRC (and many other forms of posterior uveitis) will be floaters and/or blurred vision caused by inflammatory cells in the vitreous (this inflammation in the vitreous or inflammatory cells in the vitreous is called vitritis. You can see where the vitreous is in the diagram above). You are likely to have a gradual, painless loss of vision involving one or both eyes. However, in the initial stages, you may be able to continue to see well (retain good visual acuity).

There are sometimes other symptoms which may include:

- Night blindness or Impaired vision in dim light (called nyctalopia)
- Defective colour vision and difficulty distinguishing between certain colours (called dyschromatopsia)
- Sensitivity to bright lights or glare (called photophobia)
- A perception of flickering or flashing lights (called photopsia)
- Fluctuating vision
- Pain in the eyes
- Decreased ability to judge depths
- Shimmering vision (this is difficult to describe, but some people describe it as being like looking through glass or through water)
- Distorted images (called metamorphopsia)
- Decreased peripheral vision (peripheral vision is the ability to see on either side, whilst looking forward)
- Ceiling Fan effect – when you close your eyes you are left with an image of a ceiling fan whirring around.

If you have had BSCR for some time, an ophthalmologist is likely to be able to see oval shaped spots, which are orange to cream in colour at the back of your eyes in your retina. The reason this disease is called Birdshot is because these spots resemble the pattern seen when you fire birdshot pellets from a shotgun.

Because BSCR is a rare disease, it can often be misdiagnosed in the initial stages, particularly as the 'birdshot spots' are often not clearly visible to begin with.

What Causes Birdshot Chorioretinopathy?

It is not known what causes BSCR. It is believed to be an autoimmune disease. An autoimmune disease is an illness that occurs when the body tissues are attacked by its own immune system.

The majority of people who are diagnosed with BSCR (although not all) carry an antigen called HLA- A29. An antigen is a substance that enters the body and stimulates the production of an antibody to fight what the immune system perceives as an invader. Because most people who are diagnosed with BSCR carry this antigen, it may mean that they have an inherited immune dis-regulation, and research is currently being undertaken to try and clarify this.

However, many people carry the HLA-A29 antigen and never get BSCR. It is therefore assumed that other factors must initiate the onset of the disease

(a 'trigger'). This 'trigger' may be a virus, a bacteria or an environmental factor.

Background

The first case of BSCR was described in 1949 by two ophthalmologists, Franceschetti and Bable. But it was not until 1980 when two other ophthalmologists, Ryan and Maumenee coined the term 'Birdshot' because of the resemblance of the lesions to birdshot pellets.

There is a general view amongst many researchers and ophthalmologists that BSCR is a relatively new disease, which had not occurred prior to the first description in 1949. They believe that, as the symptoms are so striking, they would have been recognised had they occurred prior to 1949.

Frequency of BSCR

BSCR is a rare disease. A rare disease is defined in Europe as: a disease affecting less than 5 per 10,000 inhabitants and is fatal or severely debilitating. Because BSCR is a relatively new disease, it is difficult to identify how many people have been diagnosed with it. Recent research (carried out by Annie Folkard and Rea Mattocks who are members of the Uveitis Information Group, www.uveitis.net and who run this website) suggests that whilst BSCR remains a rare disease under this definition, it is either increasing in incidence or being more readily diagnosed.

What is the Progress of the Disease (Prognosis)?

BSCR is a potentially blinding disease, particularly if it is untreated. There are some people in whom the disease seems to be very mild (runs a relatively benign course), with patients maintaining good eyesight (or visual acuity) with minimal medical intervention.

However, the typical course of BSCR, like other autoimmune diseases, is characterised by flare ups of inflammation inside the eye (exacerbations which cause loss of visual acuity if left untreated) and remissions. Because of this, many ophthalmologists believe in quite an aggressive approach to ensure that inflammation is kept to a minimum and the maximum amount of visual acuity can be preserved.

The most concerning issue relating to BSCR is that if left untreated, or if there are many flare ups, it can lead to macular oedema (this is a swelling of the macula layer in the eye) which can cause blindness

Who Gets BSCR?

Because of the link to the HLA-A29 antigen, which is found more frequently in Caucasians, most people with BSCR are Caucasian. There does not seem to be a gender bias, although some ophthalmologists report diagnosing more women than men.

It has been believed to date that the average age of onset of BSCR is approximately 50 to 55 years (i.e. that it usually starts in people who are aged approximately 50 to 55) and that it is a disease unlikely to affect people under the age of 35. However, Rea Mattocks and Annie Folkard have been working with patients in their 20s and 30s and are receiving reports of younger people with a diagnosis of BSCR.

Is there a Cure for BSCR?

At this moment in time, there is no known cure for BSCR. Most research being undertaken is looking at finding alternative and more effective medications that have fewer side effects. However, there is some research being undertaken to establish the genetic links and the 'triggers' for BSCR and this may lead to a cure or a prevention regime in the future.

Currently, the aim is to ensure that people with BSCR reach remission or a stabilisation of their condition. However, getting diagnosed and receiving appropriate medication can feel like a bit of a lottery.

Firstly, the condition is difficult to diagnose, due to its rarity (many doctors and opticians will never have seen a case of BSCR).

Secondly, there is still a belief amongst certain ophthalmologists that BSCR is a self-limiting disease and will eventually 'go away' or 'burn out'.

Thirdly, even if you are diagnosed, because this disease is a rare disease, newer forms of medication may be difficult to access on the NHS, as there is not a large body of evidence to support their efficacy.

Fourthly, it is our experience that each individual with BSCR responds differently to different medication regimes and has a virtually unique course that their disease follows.

Much of the treatment for BSCR, therefore, has to rely on a very strong relationship between the patient and their ophthalmologist with frequent contact and a willingness on the part of the ophthalmologist to listen to what the patient believes is going on in his/her eyes and a willingness to use newer forms of medication if the more traditional ones appear not to work.

How is BSCR diagnosed?

Because BSCR is difficult to diagnose, and is not widely known about, it may be diagnosed through 'default' – that is, all other, more common conditions that cause similar symptoms will be tested for, before BSCR is considered. Usually, the definitive diagnosis for BSCR will be made through a blood test to establish whether you test positive for the HLA-A29 antigen. You may also receive one or more of the following tests:

Fluorescein angiography (fluorescein – the type of dye that is used; angiogram – a study of the blood vessels) is an extremely valuable test that provides information about the circulatory system and the condition of the back of the eye. The test is performed by injecting a special dye, called fluorescein, into a vein in the arm. In just seconds, the dye travels to the blood vessels inside the eye. A camera equipped with special filters that highlight the dye is used to photograph the fluorescein as it circulates through the blood vessels in the back of the eye. If there are any circulation problems, swelling, leaking or abnormal blood vessels, the dye and its patterns will reveal these in the photographs. Please note that you will have yellow skin and yellow eyes for a while and your urine will be bright yellow. This is normal.

Indocyanine green angiography. This is a similar procedure to fluorescein angiography. ICG angiography uses IndoCyanine Green dye which fluoresces in the infra-red (non-visible) light. The infra-red wavelengths have the ability to penetrate the retinal layers making the circulation in deeper layers visible when photographed with an infra-red sensitive camera. **Optical Coherence Tomography.** This is a non-invasive technology used for imaging the retina, the multi-layered sensory tissue lining the back of the eye. This can determine whether you have any optic nerve damage or macular swelling.

Electroretinogram (ERG). This is a series of non invasive tests where small wires are placed alongside your eyelids and receptors are placed on your forehead and the back of your head. You will then look at a range of flickering lights and patterns. This will assess how well you have maintained your eyesight – particularly in your retina and choroid and your rods and cones.

Visual Field Test. This is a method of measuring an individual's entire scope of vision, (central and peripheral (side) vision). Visual field testing actually maps the visual fields of each eye individually
What happens once you have been diagnosed?

If you have had a full range of tests prior to diagnosis, you will have a record of how your eyes are functioning and you and your ophthalmologist will be in a good position to judge the efficacy of any medication regime. Currently, the right treatment has to be tailored to suit the individual concerned, and will depend on the results of any of the above tests. There are two specific areas that your ophthalmologist will want to address: firstly trying to reduce the inflammation and secondly trying to control your autoimmune system so it stops attacking your eyes.

The current protocol is to treat with a combination of steroids (to reduce the inflammation) and immuno-suppressants (to stop your immune system attacking your eyes). These are strong drugs and do have side-effects, so it is important that there is proper monitoring and good access to your GP, ophthalmologist and rheumatologist. The reason you are likely to need to see a rheumatologist as well as an ophthalmologist is that the rheumatologist has expertise in using immunosuppressant medications. The goal of the treatment is to find the lowest dosage of medication that will allow you to maintain your eyesight and stabilise your condition, or allow you to reach remission.

If you are put on steroids, you will also be given medication to counteract any damage to your bones that high doses of steroids may cause. These are usually alendronic acid and vitamin d and calcium tablets. If you are not given these automatically, you should ask your consultant about this. You may also be given gastric medication to counteract any effects on your stomach.

If this first line of treatment proves unsuccessful and inflammation returns, there are other medications which can be used and which may suit you better.

Unfortunately, at the moment there is no one definitive medication regime that works with everybody who has BSCR.

Monitoring

If you are taking immunosuppressants and steroids, you will be (or should be) monitored for any unwanted side effects. Your rheumatologist or ophthalmologist will advise what they should be, but they will usually include blood tests and DEXA scans. It is important to follow your specialist's instructions and get these tests done when you are told to, as they are designed to safeguard your health and are important.

Blood Tests. The Blood tests check that your kidney and liver are functioning well, measure your cholesterol levels, check your blood pressure

and the levels of the immunosuppressants in your system to make sure you are not having too much or too little. These routine blood tests are done between every 6 – 12 weeks depending on your consultant's advice and your test results. The blood tests are sometimes done by your GP and sometimes done by a specialist unit where you receive your treatment, or even by your local hospital's renal unit.

You are also likely to have regular visual field tests and/or OCTs and/or ERGs (described above). You may also be sent for further Indocyanine Green or Fluorescein angiograms.

Dexa Scan. If you have been put on oral steroids for some months, your GP should arrange for you to receive a bone density (DEXA) scan periodically (usually once a year) to check that your bones have not thinned as a result of the steroids that you have been taking. The information below explains what this involves and gives a bit more information about how it is done. You may have to ask your doctor to arrange this for you. In our experience it does not necessarily happen automatically.

What is a Bone Density Scan (DEXA)?

A DEXA scan is used to measure the density of bones. It is mainly used to diagnose osteoporosis (loss of bone material) and to assess your risk of having a fracture

It is an enhanced form of x-ray technology that is used to measure bone loss. DEXA scanning is today's established standard for measuring bone mineral density (BMD).

DEXA is most often performed on the lower spine and hips. In children and some adults, the whole body is sometimes scanned. Peripheral devices that use x-ray or ultrasound are sometimes used to screen for low bone mass. You should wear loose, comfortable clothing, avoiding garments that have zippers, belts or buttons made of metal. Objects such as keys or wallets that would be in the area being scanned should be removed.

Further information

There is a large amount of material about BSCR which can be accessed simply by typing Birdshot into your web browser.

One of the most acclaimed explanations of BSCR, written by a leading American ophthalmologist, Dr C Michael Samson, can be accessed on <http://emedicine.medscape.com/article/1223257-overview>

The international support group for people with Birdshot, run by an American, Dagmar Bogan, who has Birdshot, can be accessed on:
<http://bsrc.lefora.com/forum/category/bsrc-forum-topics/page1/>

If you have been diagnosed with Birdshot Retinochoroidopathy and want to contact another patient who has personal experience of the eye condition, Rea Mattocks or Annie Folkard can be emailed directly at:
birdshot@uveitis.net

Uveitis Information Group
South House
Sweening
Vidlin
Shetland Isles ZE2 9QE
www.uveitis.net
Tel: 0845 604 5660

The information contained in this Factsheet has been written for patients by Rea Mattocks and Annie Folkard (both patients) in conjunction with Mr Nigel Hall, Consultant Ophthalmologist at The Winchester and Eastleigh Healthcare Trust.

Published by Uveitis Information Group (UIG) October 2009